Anatomy, male

TIMOTHY McHALE AND PETER B. GRAY
University of Nevada, Las Vegas, United States

Primary human male sex characteristics are structures that aid fertilization, as when the penis becomes erect to enable intercourse and the release of gametes and other components in the semen during ejaculation. Secondary sex characteristics are structures that indirectly facilitate the delivery of gametes to the opposite sex, as when the enlarged larynx and additional upper body musculature of human males arising at puberty may have evolved to help ancestral males attract and secure mates. An evolutionary perspective suggests that many features of human male anatomy are consistent with low sperm competition pressures and mild polygyny/mostly monogamy.

Primary sex characteristics

Primary sex characteristics are defined as any structures that are involved in reproduction. For males, these include the visible external reproductive organs known as the penis and scrotum. Developmentally, the penis is homologous to the clitoris. Functionally, the penis is involved in sexual arousal, delivery of sperm to the female reproductive tract, and the excretion of urine. The outward structure of the penis consists of the shaft, head (glans), and foreskin.

The distal end of the penis, the glans penis, is bulbous, sensitive, enlarged, and has loose skin, called the prepuce (or foreskin), which covers all or part of the glans penis. The surgical removal of foreskin is known as circumcision.

The penile shaft is made up of three columns of erectile tissue, each covered with a sheath of dense, fibrous, connective tissue. This tissue is characterized by a spongy network of connective tissue and smooth muscle which contains vascular spaces. A penile erection is initiated by a complex of interacting psychological, endocrine, neural, and vascular factors that are usually, but not always, associated with various sexual stimuli, such as a tactile stimulation of the genital area. During sexual arousal, blood fills the spongy tissue and vascular spaces, causing the penis to enlarge and stiffen.

The paired dorsal columns of the penis, known as the corpora cavernosa, account for the majority of the penis's erectile capacity and are bound by fibrous tunica albuginea. This connective tissue creates resistance that limits the expansion of the corpora cavernosa and thus causes the erect penis to stiffen. The midventral column of the penis, called the corpus spongiosum, surrounds the urethra and forms the ridge along the underside of the erect penis. Here, it expands distally from the shaft to form the glans penis. At the inner end of the root of the penis it forms the penile bulb. The function of the corpus spongiosum is to keep the urethra open prior to ejaculation. Additionally, it expands during an erection, but to a much lesser extent compared to that of the corpus cavernosa.

The testes are another primary sex organ and are located in the scrotum, a loose bag of skin which hangs outside the body below the root of the penis. Two testes are located in the scrotum and are usually asymmetric in appearance: the left testicle typically hangs lower than the right testicle, while the right testicle is typically larger in appearance in comparison to the left. The location of the scrotum has strategic importance from an adaptive standpoint. The number of viable sperm testes can produce is dependent on temperature. As a result, the scrotum develops outside the body and functions to provide and maintain an overall temperature that is conducive for optimal sperm production. Specifically, the temperature of the testes remains, on average, about 3 degrees C lower than that of normal body temperature. The scrotal sac functions to regulate and respond to changes in temperature in a variety of ways. When the body is cold, the scrotum pulls the testes closer to the body, thickens the scrotal skin, and causes the sac to become wrinkled, increasing the thickness of the skin to avoid heat loss. This contraction is facilitated by

The International Encyclopedia of Human Sexuality, First Edition. Edited by Patricia Whelehan and Anne Bolin.

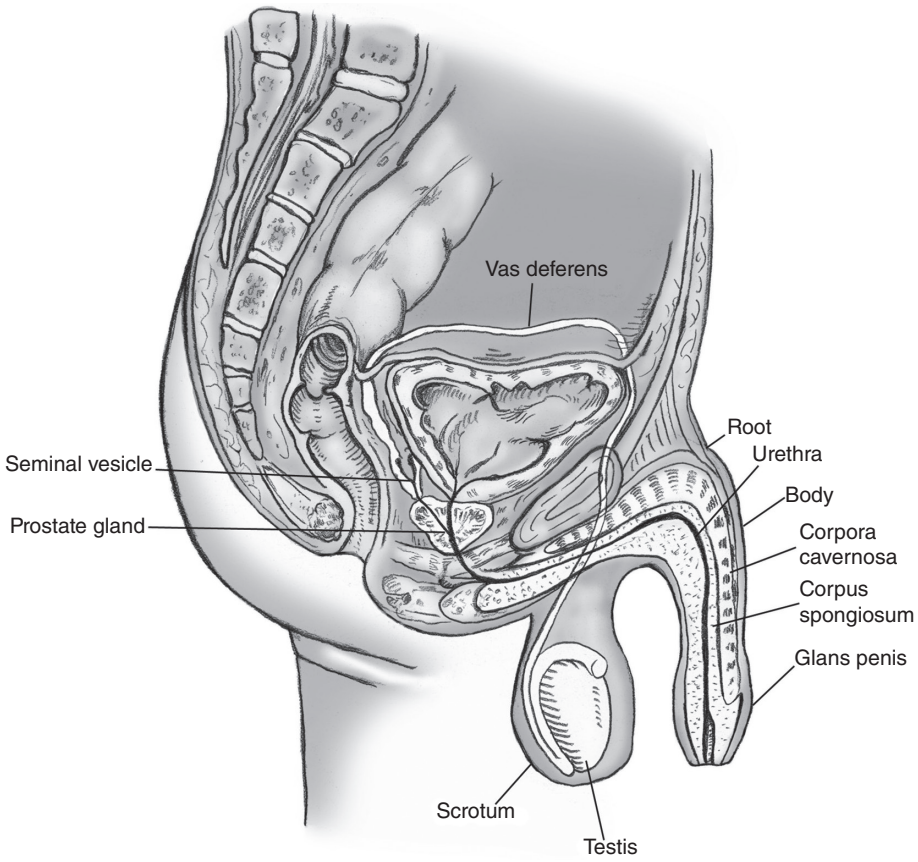

Figure 1 Reproductive organs of the human male, sagittal view.
Source: Tsaitgaist (Derivative work), via Wikimedia Commons. CC-BY-SA-3.0.

the dartos muscle, which causes the scrotal skin to thicken and become wrinkled. When warm, the scrotal skin becomes loose and flaccid, the testes hang away from the body, numerous sweat glands are initiated, and the surface area increases for cooling and temperature regulation purposes. In total, roughly 400 million sperm are produced each day in a healthy adult male. In comparison, females in natural fertility social contexts produce about 400 mature eggs in an entire lifetime.

The male duct system and accessory glands

Sperm cells must pass through the male duct system and accessory glands in order to exit the body. After leaving the testes, sperm pass through the epididymis, the vas deferens (or ductus deferens), the ejaculatory duct, and finally the urethra. When a male is sexually aroused and ejaculates, sperm are first ejaculated from the epididymis. This structure is housed behind each testis and contained within a membranous sac. Ejaculation triggers smooth muscles to contract reflexively and sperm are propelled from the epididymis into the vas deferens.

Upon entering the vas deferens tube (which is typically 45 cm long), mature sperm are carried through the inguinal canal into the pelvic cavity where it joins with the ducts of the seminal vesicles. The seminal vesicles are two small glands located behind the bladder. These vesicles secrete a viscous, nutrient-rich fluid, which account for approximately 60% of the volume of semen. The point at which the ducts of the seminal vesicles and the vas deferens meet is known as the ejaculatory ducts. It

Figure 2 Circumcised penis.
Source: By Krittika, via Wikimedia Commons. CC-BY-SA-3.0.

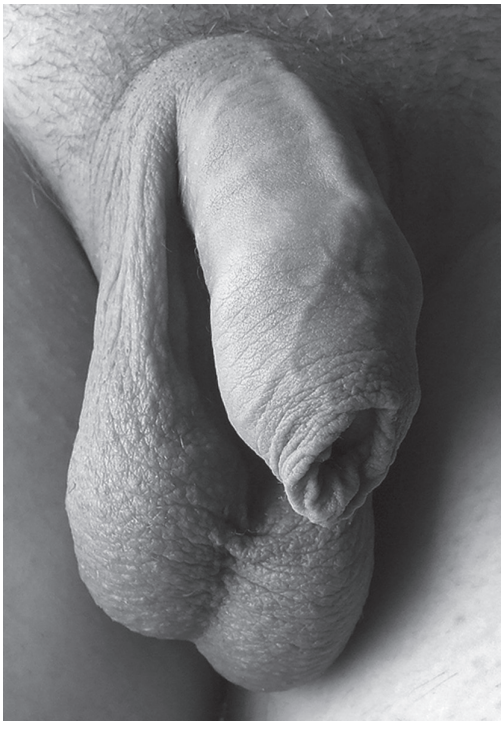

Figure 3 Uncircumcised penis.
Source: By stnu, via Wikimedia Commons. CC-BY-SA-2.0.

is at this point that these paired structures pass through the prostate and open into the urethra.

During ejaculation, the prostate gland secretes a thin, milky, alkaline fluid which enhances sperm motility and prolongs their lifespan. The walnut-sized prostate gland surrounds the urethra and is located just inferior to the bladder. The prostate gland also plays a role in the control and release of urine.

The last glands in this group are located inferior to the prostate gland and are known as the bulbourethral glands or Cowper's glands. During sexual arousal, these two, pea-sized glands secrete a clear liquid that is expelled into the urethra. Commonly referred to as "pre-cum," this fluid plays a role in lubrication and functions to neutralize acidic urine in the urethra.

The urethra is the terminal end of the male duct system and provides an exit at the opening of the penis for either urine or semen. This structure is divided into three regions: the prostatic, the membranous, and the spongy (penile) urethra. The prostatic urethra begins at the neck of the bladder and is the portion surrounded by the prostate. The membranous urethra is the intermediate part of the urethra and passes through the urogenital diaphragm. The spongy urethra is the longest of the three regions (about 15 cm). This portion runs through the penis and terminates at the external urethral orifice, which is the point where semen or urine exits the body.

When sperm passes through the ejaculatory ducts, seminal vesicles, the prostate gland, the bulbourethral glands, and mixes together with their associated fluids, semen is formed. Semen is typically a white, relatively alkaline, sticky mixture of sperm and accessory fluid which provide sperm with stored nutrients, protection, and increased motility. Semen is ejaculated from the male urethra at sexual climax.

Puberty and secondary sex characteristics

Unlike most organ systems, such as the cardiovascular, digestive, and respiratory systems, the reproductive system does not operate in a

continuous fashion from the time of birth to death. Instead, the reproductive system lays dormant until puberty. As puberty ensues, male sex hormones (e.g., testosterone) initiate the development of spermatogenesis, accessory reproductive organs, ducts, glands, and the penis to grow to adult size and function. Moreover, testosterone affects behavioral changes related to reproduction, such as heightened male libido and interest in courtship. On average, puberty, sperm production, and the development of secondary sexual characteristics initiate around age 14 in males, though population and individual variation in this aspect of male development is observed. Sperm production continues throughout life; however, as men age, the volume of sperm production and sperm motility decrease over time. When reproductive opportunities arise, sperm is delivered to the female reproductive tract via ejaculation. Sperm must be deposited a few days before or on the day of ovulation in order for the two gametes (ovum and sperm) to have an opportunity to fuse. The fusion of sperm with an ovum results in a fertilized cell, otherwise known as a zygote. Ultimately, the function of sexual reproduction is to produce a viable offspring capable of reproducing in the future.

Secondary sex characteristics are anatomical features that develop during puberty and are not directly related to reproduction and differ between the sexes. Some of these traits include: pubic, axillary, and facial hair growth, enlargement of the larynx and thickening of vocal cords (resulting in the deepening of the voice), and increased musculature. From an evolutionary standpoint, secondary sex characteristics are thought to have evolved in order to give individuals an advantage in attracting mates or by providing males an edge in male–male competition. For instance, numerous studies have shown that females are sexually attracted to males who display an increase in musculature, especially a broad chest and shoulders, and narrow hips. Female preference in male physiques most likely reflects honest signals of health, masculinity, and strength, all of which could be indicative of potential male fitness. The extra muscle mass most likely provided men with a competitive edge in access to mates in male–male competition (i.e., fighting), and may have been of considerable importance when it came to hunting and scavenging for resources. Additionally, studies have suggested that the deepening of the male voice may serve as an honest signal of age and status within contexts of male–male competition and female choice.

Other male secondary sex characteristics include greater male skeletal robustness, increased stature, enhanced jaw development, and enhanced oil and sweat gland secretion. Many of these features can be seen as enhancing success in male–male competition. The increased oil and sweat gland (e.g., apocrine gland) activity makes adult male smell more pronounced and recognizable.

Human male anatomy: The product of past selection pressures

Functional anatomy and physiology can make sense of the workings of male primary sex characteristics; these function to enhance male reproduction. Males produce large numbers of sperm and combine these with various chemicals in the semen to aid the chance of fertilization during intercourse and ejaculation. Comparative anatomy and physiology provide additional insight into the selective pressures that have shaped human male anatomy. Human males have relatively small testis size, modest seminal vesicle size, low sperm quality and other characteristics consistent with relatively low sperm competition pressures. Put another way, the recent evolutionary ancestors of humans likely had low degrees to which a given fertile female mated with multiple males.

Charles Darwin's insights regarding sexual selection help make sense of male secondary sex characteristics. In his classic book on sexual selection, *The Descent of Man, and Selection in Relation to Sex*, first published in 1871, Darwin emphasized the processes of male–male competition and female choice giving rise to sex differences such as those in body size and musculature. From the standpoint of sexual selection, human male secondary sex characteristics can be viewed as products of male–male competition and female choice, under the view that past males with more skeletal and muscular mass had

greater reproductive success. However, comparative reproductive anatomy and physiology suggest that the magnitude and nature of human male secondary sex characteristics are consistent with mild polygyny/mostly monogamy.

SEE ALSO: Primate Mating Systems; Sexual Selection

REFERENCE

Darwin, C. 1981 [1871]. *The Descent of Man, and Selection in Relation to Sex*. Princeton, NJ: Princeton University Press.

FURTHER READINGS

Dixon, A. 2009. *Sexual Selection and the Origins of Human Mating Systems*. Oxford: University Press.

Gray, P. B., and J. R. Garcia. 2013. *Evolution and Human Sexual Behavior*. Cambridge, MA: Harvard University Press.

LeVay, S., and J. Baldwin. 2012. *Human Sexuality*, 4th ed. Sunderland: Sinauer Associates, Inc.

Marieb, E., and K. Hoehn. 2007. *Human Anatomy and Physiology*, 7th ed. San Francisco, CA: Pearson Benjamin Cummings.

Morris, D. 2008. *The Naked Man: A Study of the Male Body*. New York: St. Martin's Press.